

“A Comprehensive Reveal: Early Detection Of Glaucoma using SVM”

Senthi Vadivu M¹, Dr.Jamuna Rani M², Pooja Dixikha G³, Namtha P V⁴

^{1,2}Assistant Professor, Department of ECE, Sona College of Technology, salem,

^{3,4}Department of ECE, Sona College of Technology, Salem

Article History: Received: 10 January 2021; Revised: 12 February 2021; Accepted: 27 March 2021; Published online: 28 April 2021

ABSTRACT:

Eyes are our body's most importantly developed sensory organ. A far large part of the brain is dedicated to vision, other sensory activities such as hearing, taste, touch, or smell combined. This precious organs affected by various reasons. Glaucoma is a category of eye disease that causes damages to the optic nerves, the protection of which is critical for proper vision. This collision is often triggered by unusually high pressure in your eye. Glaucoma also known as the “Silent Thief of Sight,” is one of the leading cause of blindness in the world for people above the age of 60. The cost of detecting glaucoma using optical coherence tomography (OCT) and Heidelberg Retinal Tomography (HRT) technique is prohibitively high. The aim of this study is to uncover and explore the early detection of glaucoma using the Support Vector Machine (SVM) classifier process, which are a type of Supervised learning method. Furthermore, the SVM classification process is straightforward, with high precision and first-rate performance.

Keywords: Glaucoma, Optic nerve, Support Vector Machine, Image Processing, Preprocessing, Classification

1. Introduction

Glaucoma is a eye disease that cause damages to the optic nerves. When a person's health deteriorates, his or her vision becomes completely compromised. This harm is often caused by excessive weight in the eye. Although everybody has a 2.3 percent lifetime risk of glaucoma, first degree relatives (fdr) of glaucoma have a tenfold increase in risk of glaucoma. As a result, making FDRs aware of the need for glaucoma tests, which include an evaluation of the optic nerve, can save the vision of a large number of people. Glaucoma is the most leading causes of vision impairment in people above the age of 60. Neuron degeneration of the body's optic nerve causes eye disease. Images are sent to the brain via the optic nerve. If the injury is severe enough, it will result in permanent blindness. Intraocular pressure (IOP), visual area, and cup-to-disc ratio are all factors in determining glaucoma (CDR). Glaucoma increases the CDR value, which affects peripheral vision loss. CDR values can be calculated using Image Processing technique. These CDR values can be used to screen for glaucoma. Pre-processing, attribute extraction, and classification are examples of traditional image processing techniques.

1.1 Types of Glaucoma:

There are two main types of Glaucoma:

- Open angle Glaucoma
 - Normal Tension Glaucoma
- Closed angle Glaucoma
 - Primary angle –Closure Glaucoma
 - Intermittent angle closure Glaucoma
 - Acute angle closure Glaucoma
 - Creeping angle closure Glaucoma

Open Angle Glaucoma:

Open angle glaucoma is a chronic, progressive, and long lasting multifactorial optical neuropathy pointed by a anterior chamber open angle, optical nerves head changes, progressive loss of peripheral visions, and central visual field losses. The drainage angle established by the cornea and iris is unimpeded, but the trabecular meshwork is partly blocked. As a result, the pressure in the eye steadily rises. The optic nerve is damaged as a result of this strain. It is the most prevalent form of glaucoma and is also known as wide-edge glaucoma. The trabecular meshwork (the channel structure in the eye) seems natural, but liquid does not flow out as it should.

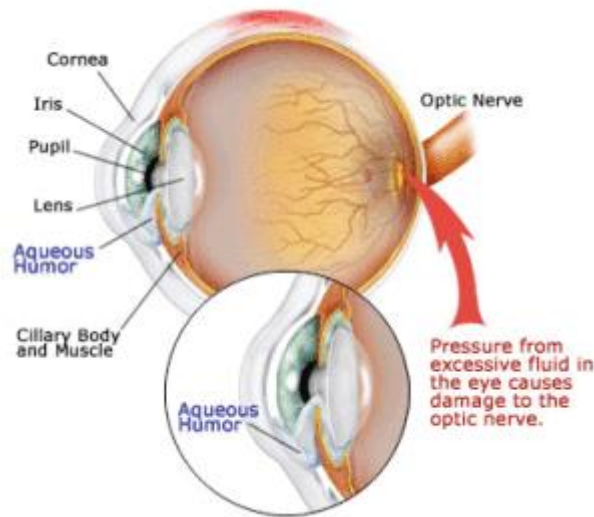


Figure1 Signs of Open Angle Glaucoma

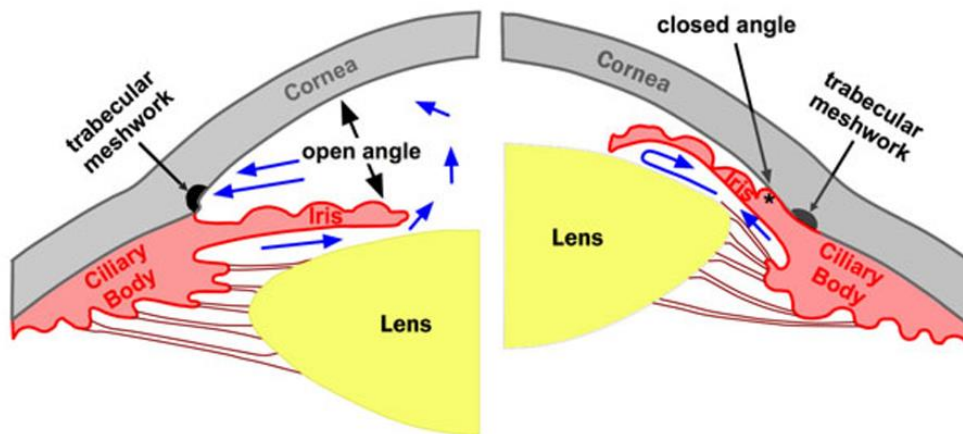


Figure2 Open and Closed Angle Glaucoma

1.2 Open and closed angle Glaucoma

The iris is in the correct location in open-angle glaucoma, and the uveoscleral drainage canals are clear. The trabecular meshwork, on the other hand, isn't draining properly. The iris is pressed against the cornea in closed angle glaucoma, blocking the uveoscleral drains and the trabecular meshwork.. It may be called as intense or interminable edge conclusion or tight point Glaucoma. The channel space between iris and cornea becomes excessively thin and this leads to abrupt development of weight in eye.

2. LITERATURE REVIEW

The authors developed a novel method for [1] Automated Diagnosis of Glaucoma by Using Empirical Wavelet Transform , Correntropy Features Extracted from Fundus Images (Shishir Maheshwari et al, 2016). Glaucoma is automatically detected by the method of Empirical Wavelet Transform (EWT).[2] novel method for glaucoma detection using a mixture of Higher Order Spectra (HOS) features from digital fundus image (U.Rajendra Acharya et al, 2011). For the improvement of image contrasting, histogram equalization and radon transform is performed for HOS feature extraction . The classification accuracy level for z-score normalized data achieved 91.7% by Random forest classifier method.[3]Optical cup , optical disc segmentation using superpixel classifications for glaucoma screening (Jun Cheng et al, 2013). In optical disc segmentation, histogram, center surrounded statistic are used to classify each superpixel as disc or nondisc. A self-assessment reliability points are calculated to the quality of the automated optical disc segmentation [4]Automatic identification of normal and glaucoma classes using Higher Order Spectra (HOS) and Discrete Wavelet Transform (DWT) feature (M. R. K. Mookiah et al, 2013). The extracting features are fed to the Support Vector Machine (SVM) classifier with linear order and polynomial order 1, 2, 3 and Radial Basis Function (RBF) to select the best kernel function for automatic decision making. HOS consisting of moment and cumulant spectra. It can be used for both the deterministic signals and random signal.[5]Novel techniques is to extract the energy signatures obtained using 2-D discrete wavelet transform, and subjectsof these signatures to

different feature ranking and feature selection strategies (Sumeet Dua et al, 2012). And have the effectiveness of the resultant ranked and selected subsets of features using a support vector machine, sequential minimal optimization and random forest and naive Bayes classification strategies. Discrete wavelet transform used to decomposed the signal then using a fourth-order symlets, wavelet is used to extract the features and to analyze the discontinuities and abrupt changes contains in a signals.

3. PROPOSED METHODOLOGY

Proposed Glaucoma Detection System

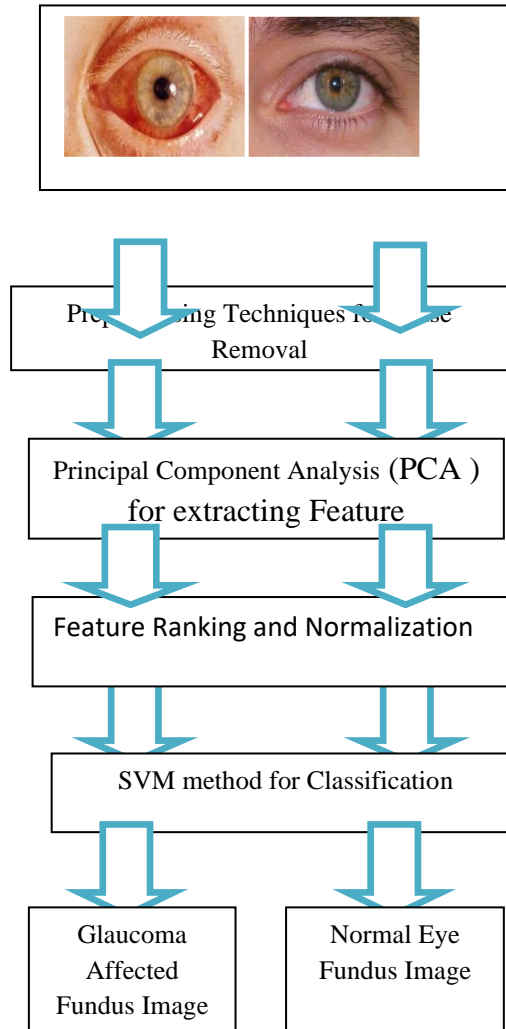


Figure 3Block Diagram of Proposed System

Preprocessing:

Pre-processing is usually done before the main processing of the image. It is normally done to remove unwanted portions of the image to be processed. This helps in improvement of the image. Pre-processing is a term used to describe processes of images at the most basic level of complexity, where all input and output are intensity image. Aim of pre processing to boost the images data by suppressing undesirable distortions or enhancing certain images feature that is necessary for subsequent process. A digital fund camera, which collects the light reflectance, is used to collect retinal images.

Feature Extraction:

The extraction of the region of interest for further processing is aided by feature extraction. Since it reflecting the transition from pictorial to non-pictorial data representation, it has an important phase in mostly in computer vision and image processing solutions. Following that, Representation will be used to perform a number of patterns recognition and classification techniques.

Optic-Cup Segmentation:

Segmentation of the Optic- Cup is difficult due to density to blood vessels lining areas of the cups and gradual difference in colour strength between the surface and cup. The kinks in a blood vessels will also aid in the

identification of cup borders. The white cup like region the middle of the optical disc is known as the optic-cup. The optical cup-to-disc ratio (C/D) is a glaucoma diagnostic test that compares the size of optical cup to the size of optical disc.

Optic-Disc Segmentation:

The optic-disc is regarded as one of the most essential components of the retinal picture. The Optical-Disc is regarded as a pre-processing factor of various methods of retinal image segmentation. It is a standard technique in retinal image screening. The Optical-Disc is shaped like a vertical oval (elliptical). It is separated into two zones: the central zone (cup) and the periphery zone. Presence of Glaucoma is indicated by the variations in colour, shape or depth of Optic Disc.

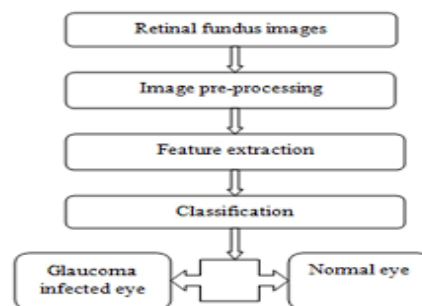
Cup to Disc Ratio:

In optometry and ophthalmology, the CDR calculation is used to track glaucoma movement. The optic circle is a zone that belongs to the anatomical area of the eye's "vulnerable limb." The "vulnerable side" in the region of the retina where the optic vein and nerve enter. The CDR ratio is concerned with the area between the cup and the optic circle, and hence the width of the optic plate. The presence of Glaucoma is shown by a high CDR value..

Classification:

Its is an one of the important step for decision making process. The classifier used here is SVM(support vector machine)and its is a basic classifier. Supervised learning model associated with learning algorithms which evaluate data used for classification analysis and regression analysis

3.1 FLOW DIAGRAM:



The picture to be analysed is collected is in form of a raw image. From the input image, the area of interest is extracted. Optical disc and optical cup are the areas of concern in glaucoma diagnosis. These are used to calculate CDR values. The input image is graded as normal or glaucoma affected based on the CDR values. There are a number of methods available in image processing. The techniques utilized in detection of glaucoma are Image Enhancement, Image Segmentation, Feature extraction, Morphology, etc.

Degeneration of optic nerves causes Glaucoma. Therefore the fall in cardiovascular system to the nervous optics accommodate the field of vision surrenders related with glaucoma. Morphological features of fundus images are fiber. Glaucoma are often detected using the subsequent often wont to detect the damage caused to nervous optics features,

- Cup-to-disc ratio (CDR)
- Ratio between area of blood vessels in inferior-superior side and the nasal-temporal side
- Ratio of distance between the optic disc center and optic nerve head to diameter of the optic disc

The two main components used in the diagnosis of glaucoma are the Optical Cup and the Optical Disc. The Optical Cup and Optic Disc is used to segment images. This aids in the computation of CDR (cup-to-disc) value. Changes in CDR value are seen as an important indicator of glaucoma.

4.OUTPUT DESCRIPTION

4.1 INPUT IMAGE ACQUISITION

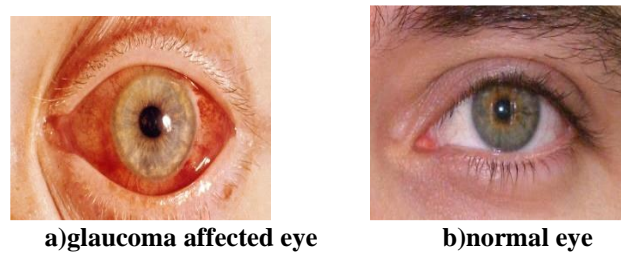

Figure 4 INPUT IMAGES

Glaucoma is observed in the above image, and hence the corresponding disc section image, disc boundary, cup image, and cup boundary are known.

4.2 IMAGE WITH GLAUCOMA:

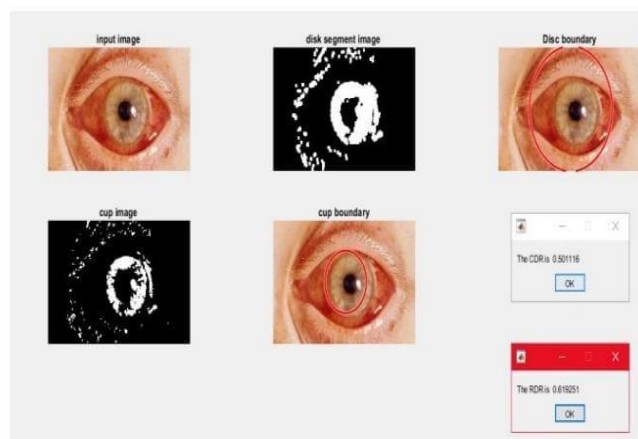


Figure5 Glaucoma Detected Eye




Figure6 Presence of Glaucoma

The output image acquired for Glaucoma affected eye is given in FIG 3.3. As per the details given in Fig 3.3, the to detect the presence of Glaucoma. presence of Glaucoma is detected. The key factor for glaucoma detection is the CDR value. Glaucoma is shown by a CDR value greater than 0.4. There is a chance of Glaucoma since the value here is 0.87594, which is higher than 0.4.

4.3 IMAGE WITHOUT GLAUCOMA

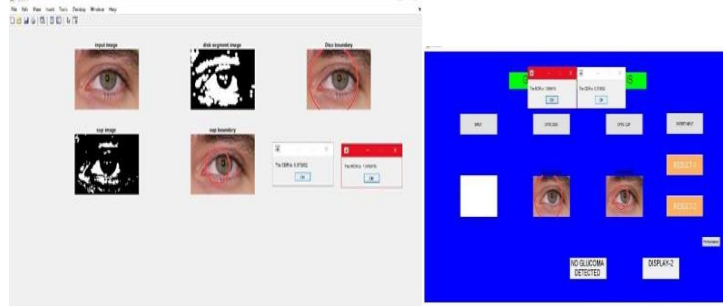


Figure7 Normal Eye Figure8 Normal Eye with CDR value

Figure4.5 shows the output image with a human eye. The CDR value in this case is 0.266856. There is no chance of Glaucoma if the CDR value is less than 0.4. Table4.1 depicts these specifics. Table 4.1: CDR Values

CDR	RESULT
0.51162	Glaucoma
0.32152	Normal
0.71129	Glaucoma
0.56791	Glaucoma
0.23827	Normal
0.31567	Normal
0.65421	Glaucoma
0.24002	Normal
0.37143	Normal
0.87594	Glaucoma

About 10 images were taken as input. And as per the CDR values the presence of Glaucoma is detected. When the CDR value falls in the range of $0.1 >$ and ≤ 0.4 , then there is no risk of Glaucoma. The eye is Normal. Whereas when the CDR value is above 0.4, then there is a risk of Glaucoma.

CONCLUSION:

Every year on March 12, World Glaucoma Day is observed to raise awareness about glaucoma and to remind everyone to have daily eye (and optic nerve) check-ups in order to diagnose glaucoma as early as possible. Glaucoma is one of the most common causes of permanent blindness, but the damage can be minimised and vision retained with proper treatment. Glaucoma of spectacle is one of the silent robbers. As a result, early detection of glaucoma is critical for preventing irreversible eye damage. The eyes, with which we sight the world, are the most complex, subtle and sensitive organs in our human being body. In this research paper, the aim was to reveal, first and foremost, glaucoma detection using SVM method. Glaucoma is caused by the degenerations of the optical nerve in the eye. This could result in irreversible vision loss. As a result, early diagnosis of this condition aids in the prevention of vision loss. CDR is used as the primary parameter in this study to detect the presence of glaucoma. There are several characteristics that aid in the diagnosis of glaucoma.

REFERENCES:

1. Shishir Maheshwari, Ram Bilas Pachori, U Rajendra Acharya, "Automated Diagnosis of Glaucoma Using Empirical Wavelet Transform and Correntropy Features Extracted From Fundus Images", 2017
2. U. Rajendra Acharya; Sumeet Dua; Xian Du; Vinitha Sree S; Chua Kuang Chua, "Automated diagnosis of glaucoma using texture and higher order spectra features", 2011
3. Jun Cheng; Jiang Liu; Yanwu Xu; Fengshou Yin; Damon Wing Kee Wong; Ngan-Meng Tan; Dacheng Tao; Ching-Yu Chen, "Superpixel Classification Based Optic Disc and Optic Cup Segmentation for Glaucoma Screening". 2013
4. M. R. K. Mookiah et al., "Automated glaucoma detection using hybrid feature extraction in retinal fundus images", 2013.

5. Sumeet Dua; U. Rajendra Acharya et al., " Wavelet-Based Energy Features for Glaucomatous Image Classification" , 2011
6. Juan Carrillo, Lola Bautista, Jorge Villamizar, Juan Rueda, Mary Sanchez and Daniela Rueda, "GLAUCOMA DETECTION USING FUNDUS IMAGES OF THE EYE" pp.4 2019.
7. Carlos M. Travieso, Jesus B. Alonso-Hernández, "A Novel Approach to Detect Glaucoma in Retinal Fundus Images using Cup-Disk and Rim-Disk Ratio"- International Work Conference on Bio-inspired Intelligence (IWOBI),2015.
8. Maya Jeyaraman, William G Hodge, Cindy Hutnik, John Costella, and Monali S Malvankar-Mehta. The effectiveness of teleglaucoma versus in-patient examination for glaucoma screening: a scientific review and meta-analysis 2014.
9. Khan F., Khan S.A., Yasin U.U., Haq I. Qamar U. "Detection of glaucoma using retinal fundus images", The IEEE Biomedical Engineering International conference (BMEiCON 2013), pp. 4 October 2013.
10. R. Manjula Sri, Ch. Madhubabu, and KMM Rao: "Lab VIEW based assessment of Cup to Disc Ratio for the detection of Glaucoma"-Proceedings of IEEE International Conference on Emerging trends in Computing, Communication and Nanotechnology (ICECCN2013) during 25 March 2013 at Tuticorin, TamilNadu.
12. VahabiZ, "The new approach to Automatic detection of Optic Disc from non-dilated retinal images "Proceedings of the 17th Iranian Conference of Biomedical Engineering (ICBME2010), 3 November 2010.
13. Engineering (ICBME2010), 3 November 2010.
14. J. L Starck, M. Elad, and D. Donoho, "Redundant multiscale transforms and their application for morphological component separation," *Adv. Imag. Electron. Phys.*, vol. 132, pp. 132–195, 2004.
15. Y. Xu, Y. Qiu, and X. Zhao, "The effectiveness of redundant information in text classification," in *Proc. IEEE Int. Conf. Granular Comput.*, 2012, pp. 579–584.
16. M. Sady's, A. Strzelczak, A. Grinn-Gofro'n, and R. Kennedy, "Application of redundancy analysis for aerobiological data," *Int. J. Biometeorol.*, vol. 59, no. 1, pp. 25–36, 2015.
17. R. F. Bloch, D. Hofer, S. Feller, and M. Hodel, "The role of strategy and redundancy in diagnostic reasoning," *BMC Med. Educ.*, vol. 3, no. 1, pp. 1–12, 2003. doi:10.1186/1472-6920-3-1